

Research Article

Open Access

Faezeh Nemati Karimooy*, Alireza Ebrahimzadeh Bideskan, Abbas Mohammadi Pour, Seyed Mahmoud Hoseini

Neurotoxic Effects of Stanozolol on Male Rats' Hippocampi: Does Stanozolol cause apoptosis?

<https://doi.org/10.1515/bmc-2019-0009>

received November 27, 2018; accepted February 3, 2019.

Abstract: Stanozolol is an anabolic-androgenic steroid which is commonly abused by athletes for improved energy, appearance, and physical size. It has been previously shown to cause changes in behaviour and has various physical effects. Studies have previously been conducted on its neurotoxic effect on the central nervous system (CNS), which are typically psychological in nature. This study was performed to investigate the apoptotic effect of stanozolol on different parts of the rat hippocampus. Sixteen male Wistar rats were divided randomly into two groups (experimental and control). The experimental group received subcutaneous injections of stanozolol (5mg/kg/day) for consecutive 28 days, whereas the control group received saline using the same dosing schedule and administration route. After routine procedures, coronal sections of rat brain were stained with Toluidine blue and TUNEL for pre-apoptotic and apoptotic cell detection, respectively. In order to compare groups, the mean number of TUNEL-positive and pre-apoptotic neurons per unit area were calculated and analysed. Histopathological examination revealed that the mean number of pre-apoptotic and apoptotic neurons in the CA1, CA2, CA3 and DG areas of the hippocampus were significantly increased in the stanozolol treated group. In conclusion, stanozolol abuse may induce pre-apoptotic and apoptotic cell formation in different regions of the hippocampus.

Keywords: Anabolic-Androgenic Steroids; Stanozolol; Apoptotic cells; Pre-apoptotic Cells; Hippocampus.

*Corresponding author: Faezeh Nemati Karimooy, Mashhad University of Medical Sciences, Mashhad, Iran, E-mail: Nematif871@gmail.com

Alireza Ebrahimzadeh Bideskan, Abbas Mohammadi Pour, Seyed Mahmoud Hoseini: Mashhad University of Medical Sciences, Mashhad, Iran

Introduction

Anabolic-androgenic steroids (AASs) are a group of hormones which include natural male hormone, testosterone and testosterone synthetic derivatives which have been synthesized over the last seven decades. These compounds have both anabolic (muscle building) and androgenic (masculinizing) effects [1].

AASs are used clinically for androgen replacement therapy (ART) and pharmacological androgen therapy (PAT) [2]. Due to their muscle hypertrophy effects and ergogenic properties, AASs are widely used among athletes, in particular, bodybuilders. Moreover, these compounds rapidly increase muscle mass and decrease body fat percentage simultaneously, beyond the rate which can be obtained naturally [1, 3, 4].

Misuse of AASs has been escalating in athletes and the younger population, therefore it is vital to investigate the potential side effects [1]. One of the most popular members of the AAS family is stanozolol which is used by athletes in high doses for boosting their energy and improving their physical appearance and size [5]. Despite being a banned substance by the International Olympic Committee since 1974, stanozolol is one of the most commonly abused synthetic AASs in sport [6].

Stanozolol (5 α -androstane-17 α -methyl-17 β -ol[3,2-c]pyrazole) is a heterocyclic AAS first synthesised by Clinton in 1959 (Figure 1). Its chemical structure is different from both intrinsic and most extrinsic steroids [6]. These steroids are transferred to the nucleus as the hormone-receptor complex through the intracellular receptor and induce protein synthesis leading to the construction of new proteins [1]. Therapeutic effects have been reported in osteoporosis, protein deficiency, increasing appetite and weight, inherited angioedema and specific kinds of anaemia [6-8].

The impact of stanozolol is dose-related; however, it might be affected by individual susceptibility and other negative habits like alcoholism [8]. Reports have shown that the use of this drug could induce physical and histological damage, in addition to behavioural disorders.

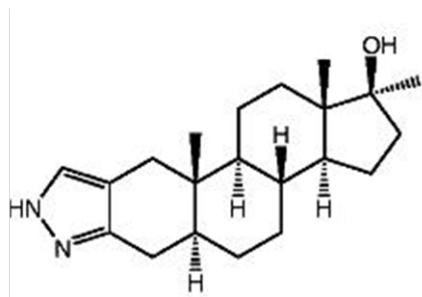


Figure 1- The chemical structure of stanozolol.

In animal studies, stanozolol caused male sexual behaviour to decrease by suppressing the serum level of testosterone [9]. In addition, depression, anxiety, paranoia, aggressive behaviour and somatic disorders are the most common complaints which athletes present during the usage period of stanozolol and other AASs [10].

Reported physical side effects include constructive effects on the cardiovascular system, decreased serum apolipoprotein A1 and increased serum apolipoprotein B, hepatotoxicity and nephrotoxicity [5, 11-16]. These side effects occurred during the treatment of hereditary angioedema, compromised menstrual disturbances and virilism in women and the elevation of creatine phosphokinase (CPK) in men [17].

To date, there have been few studies conducted on the neurotoxic impacts of stanozolol, as most of these impacts are psychological and behavioural [18]; and whether AASs are neurotoxic has yet to be elucidated. One study substantiated that these compounds, including stanozolol, increased the vulnerability of neurons in response to the extracellular stimulations thus facilitating neural death, followed by acute or chronic CNS disorders [19]. Furthermore, it has been found to lead to a decline in the neurotrophic factors derived from the brain in the hippocampus and the prefrontal cortex, and reduces interactions between the low-affinity receptor and corticosteroids in the hippocampus. In addition, it increases the morning plasma level of corticosteroids [4].

Since the hippocampus plays a role in the transferral of information from short-term to long-term memory, its damage decreases the ability to memorise in the long-term and causes anterograde and also retrograde amnesia [20, 21].

Based on the role of the hippocampus in memory [21] and the studies that report memory dysfunction related to using AASs [22], we investigated the apoptotic effects of stanozolol (as a probable reason of hippocampal dysfunction) on the hippocampus. For this purpose, we

decided to semi quantitatively evaluate the apoptotic effects of stanozolol using a dose commonly abused by athletes, on different parts of the hippocampus using a male rat model.

Materials & Methods

Animals and Treatment

The Wistar rat was chosen as the animal model in accord with previous studies [23]. Although 12 rats were sufficient for statistical power [23], to perform this interventional study 16 male Wistar rats (weighing between 200-250 g) were purchased from the animal centre of Mashhad University of Medical Sciences. Animals were divided into two groups of eight by simple random sampling and dosed daily for a total of 28 days.

Animals were kept in under standard laboratory conditions, including a room with an air ventilator, between 50-60% humidity, a temperature of 22-24°C, 12-hour light:dark cycles and access to food and water *ad libitum*.

Ethical approval: The research related to animals use has been complied with all the relevant national regulations and institutional policies for the care and use of animals.

Chemicals and Preparation

Stanozolol (Sterug Pharma Company, US) was diluted with 0.5cc of normal saline for daily administration.

Experimental Procedure

The control group was administered subcutaneous saline (0.5cc) daily and the experimental group was administered subcutaneous stanozolol (5 mg/kg/day diluted with 0.5cc saline), for a total of 28 days. This dose was consistent with the equivalent human dose (based on mg/kg of body weight) which is reportedly abused among athletes [4, 9, 24-26] by subcutaneous injection therefore, we chose this route of administration [27]. Our 28-day dosing schedule was in line with previous studies evaluating the effect of stanozolol and other AASs [4, 28].

Tissue Collection and Processing

At end-point and under the approval of the ethical committee of Mashhad University of Medical Sciences, all animals were euthanized with chloroform and brains were dissected from the crania and fixed in 10% formalin solution. The dehydration process was performed as standard, and the samples were then embedded into molten paraffin. A microtome was used to cut 5 μm serial coronal sections. Slides were created from tissue slices for cell staining [29, 30].

Apoptotic Cell Staining

After preparing the slides, Terminal Deoxynucleotidyl Transferase-mediated Nick End Labelling (TUNEL) staining was performed as standard to visualize apoptotic neurons [23].

In brief, sections were deparaffinised and hydrated as standard, and peroxidase activity blocked using H_2O_2 3% in 15 minutes. Sections were washed with PBS (Phosphate Buffered Saline) and then incubated 20 minutes with Proteinase K (Fermentas, US) in room temperature. This was followed by another PBS wash and staining using the TUNEL kit solution (Roche Diagnostics, Germany). Sections were washed again with PBS and then Converter-Peroxidase solution (Merck, US) was added for 15 minutes in room temperature. After that, samples were incubated with DAB (3,3'-diaminobenzidine) substrate followed by a rinse using running water. Haematoxylin was used to create a background stain and then rinsed with running water. Sections were then dehydrated with alcohol and cleared with Xylene. Light microscopy was used to image the sections, cells with brown nuclear staining indicated apoptotic cells.

Toluidine Blue Staining

Toluidine blue staining was used to detect dark neurons [31-34] defined as pre-apoptotic cells which have undergone apoptotic changes but had not complete the process. These neurons appear darker via light microscopy as they absorb more colour (toluidine blue).

In brief, sections were deparaffinised and hydrated, then stained with toluidine blue as standard [23].

Scoring Apoptotic and Pre-apoptotic Cells

After TUNEL staining, slides were prepared for light microscope imaging. Apoptotic cells were counted in different parts of the right hippocampus under x40 magnification. Images were taken and scores were recorded. Please note, the right hippocampus was studied in all slides to ensure experimental uniformity. The pre-apoptotic and TUNEL-positive cell density was estimated by unit area via a grading system containing unbiased frames and via morphometric methods. Cell means were calculated per unit area for different parts of the hippocampus using the formula below:

$$NA = \frac{\sum \bar{Q}}{a/f \cdot \sum P}$$

NA: numerical aperture

ΣQ : number of cells counted in a slice

a/f: area in relation to each frame

ΣP : number of frames counted

Data and Statistical Analysis

All statistical analyses were performed using SPSS (Statistical Package for the Social Sciences) software (version 16) using *t*-test. Results were considered statistically significant if the p-value (predictive value) was estimated as less than 0.05.

Results

Results of the TUNEL Assay Analysis of Apoptotic Cells

The mean number of TUNEL positive cells in the unit area (NA) of CA1, CA2, CA3 and DG parts of hippocampus were estimated via light microscopy. In comparison with the control group, the mean number of TUNEL positive cells in these areas had dramatically increased in the stanozolol group (Figures 2, 3, 4 and 5). Statistical analysis indicated a significant increase in stanozolol group compared to the control for all areas (Figure 6).

Toluidine Blue Analysis of Pre-apoptotic Cells

In both treated and control groups, the number of pre-apoptotic cells was estimated by unit area(NA) inCA1,

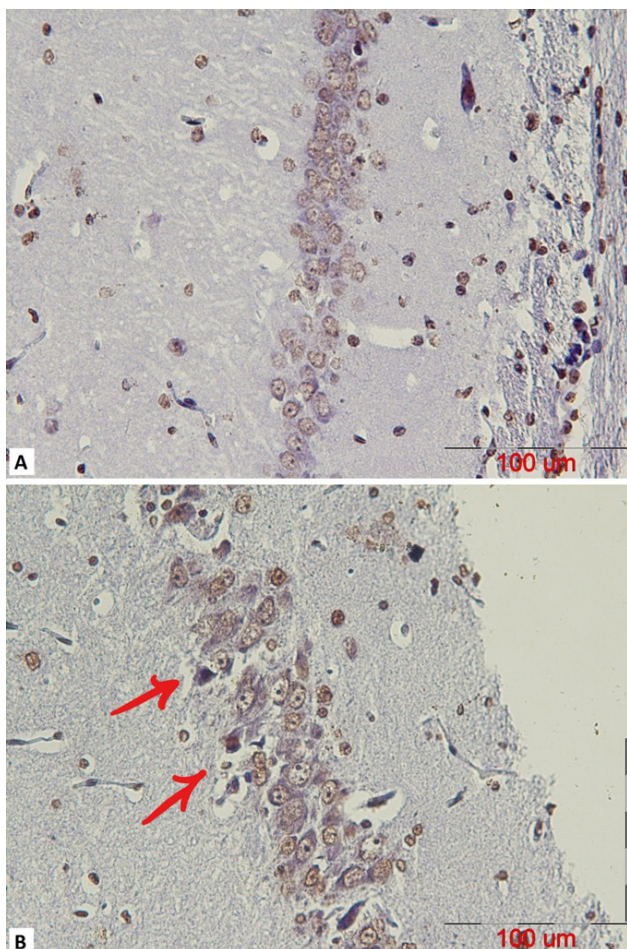


Figure 2: A representative coronal section of the CA1 part of a mature male rat's hippocampus which was stained using a TUNEL assay to observe apoptotic cells in (A) control and (B) stanozolol treated groups. The arrows indicate TUNEL positive cells with dark brown nuclei (scalebar=100 μ m).

CA2, CA3 and DG parts of the hippocampus. In the control group, there were only few pre-apoptotic cells whereas in the treated group the number increased statistically significantly for each area of the hippocampus (Figures 7, 8, 9, 10 and 11).

Discussion

We have found that stanozolol induces neuronal histopathologic changes by inducing apoptotic and pre-apoptotic cells in all areas of the hippocampus. These changes were the result of daily injections of stanozolol to male adult rats for a total of 28 days. Histological evaluation of the hippocampi by TUNEL and toluidine blue assay revealed a statistically significant increase

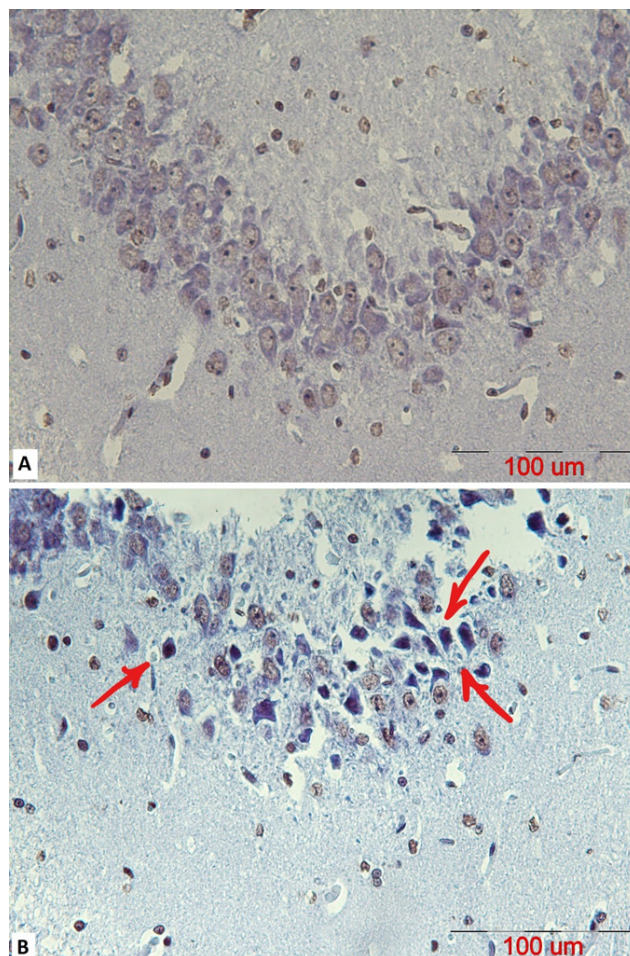


Figure 3: A representative coronal section of the CA2 part of a mature male rat's hippocampus stained using a TUNEL assay to observe apoptotic cells in (A) control and (B) stanozolol treated groups. The arrows indicate TUNEL positive cells with dark brown nuclei (scalebar=100 μ m).

in the number of apoptotic and pre-apoptotic cells, respectively, in the drug treated group.

Previous literature on the neurotoxic effects of stanozolol on the CNS, are from the psychological viewpoint [18]. Here, for the first time, the apoptotic effect of stanozolol in the hippocampus has been investigated and semi quantitatively assessed.

In the study by Matriscano, it was shown that stanozolol induced changes in the hippocampus, related to the pathogenesis of major depressive disorder. In addition, these changes were prevented by the simultaneous administration of clomipramine as an antidepressant agent. Currently, concerns are rising that AASs can cause depression, regardless of risk factors [4].

In line with our research, the results of Dr. Zaugg et al. confirmed the apoptotic effects of stanozolol and showed

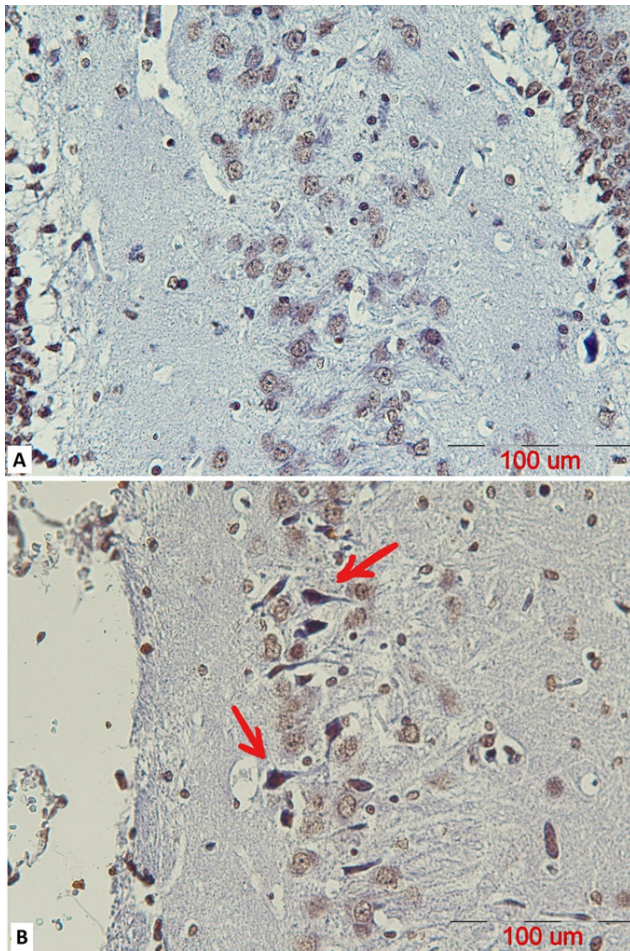


Figure 4: A representative coronal section of the CA3 part of a mature male rat's hippocampus stained using a TUNEL assay to observe apoptotic cells in (A) control and (B) stanozolol treated groups. The arrows indicate TUNEL positive cells with dark brown nuclei (scalebar=100 μ m).

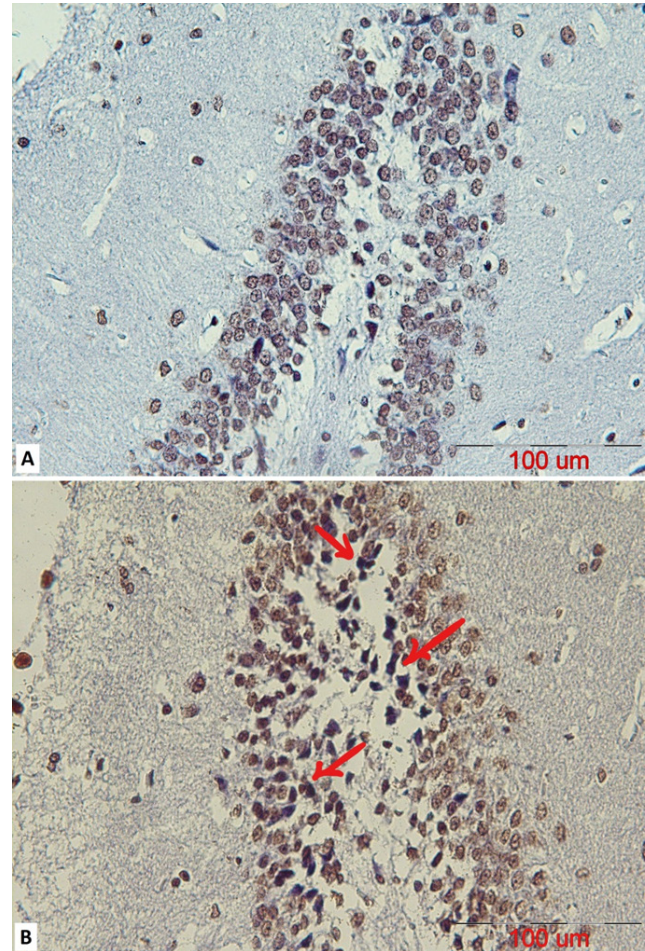


Figure 5: A representative coronal section of the DG part of a mature male rat's hippocampus stained using a TUNEL assay to observe apoptotic cells in (A) control and (B) stanozolol treated groups. The arrows indicate TUNEL positive cells with dark brown nuclei (scalebar=100 μ m).

for the first time that AASs induce apoptosis in a dose-dependent manner [13]. The *in vitro* exposure of the adult male rats' myocytes to stanozolol, in addition to other AASs, was evaluated and the number of the apoptotic cells was assessed by TUNEL assay, which was higher than the control group. In addition, the evaluation of gene expression through the formation of complementary DNA (cDNA) transcripts from RNA (reverse transcription-PCR) was shown that these compounds increase the expression of the Bax-alpha which is a pre-apoptotic oncogene [13].

Dr. Orlando et al. have shown that neural vulnerability to an extrinsic cytotoxic stimulus was boosted in presence of AASs, and therefore facilitated neural death and subsequent acute or chronic CNS disorders [35]. Another study with similar results suggested that AASs, including stanozolol, enhanced neural damage leading to acute or

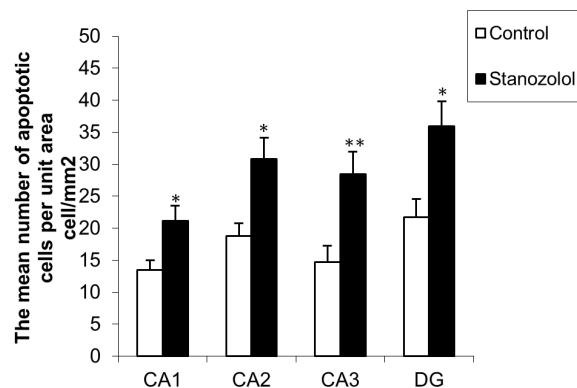


Figure 6: The comparison of the mean number of apoptotic cells in the stanozolol group versus the control group in CA1, CA2, CA3 and DG of parts of mature male rats' hippocampus (mean \pm SEM). Stanozolol treatment resulted in a statistically significant increase in the number of apoptotic cells in each brain area, when compared to the control group (* $PV < 0.05$ for CA1, CA2 and CA3, ** $PV < 0.01$ for CA3).

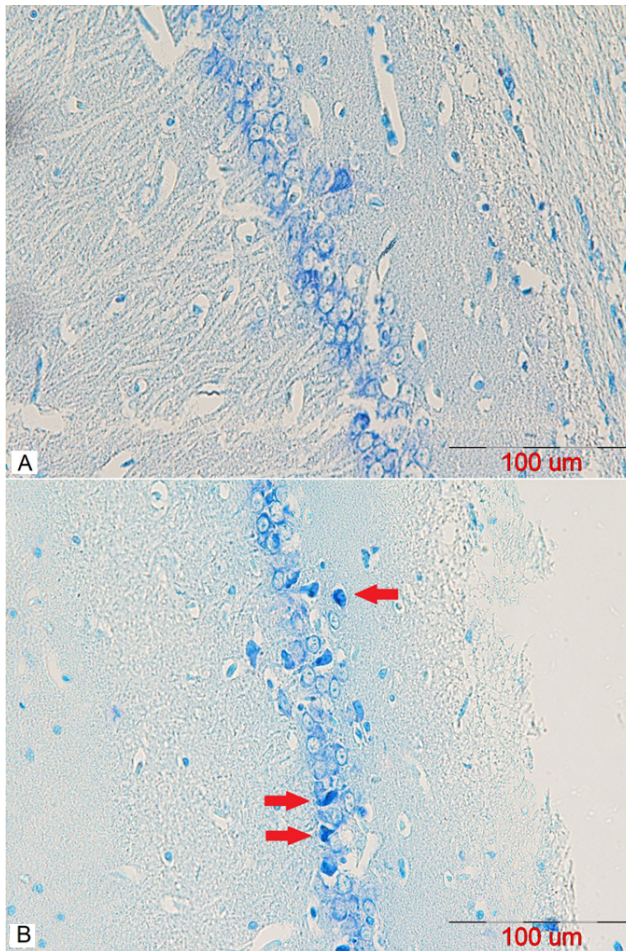


Figure 7: A representative coronal section of the CA1 area of a mature male rat's hippocampus stained using Toluidine Blue to observe pre-apoptotic cells in (A) control and (B) stanozolol treated groups. The arrows indicate dark neurons (scalebar=100µm).

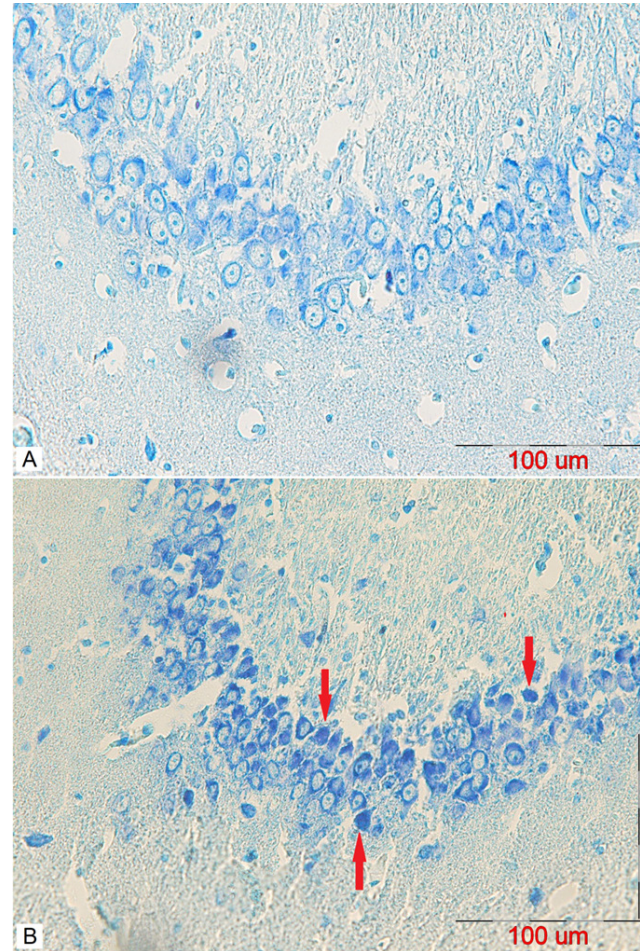


Figure 8: A representative coronal section of the CA2 area of a mature male rat's hippocampus stained using Toluidine Blue to observe pre-apoptotic cells in (A) control and (B) stanozolol treated groups. The arrows indicate dark neurons (scalebar=100µm).

chronic CNS disorders [19]. These studies are in line with our results confirming an increase in neural death.

Research by Gomes et al. also supported stanozolol-induced neural damage, where chronic exposure to AASs may cause psychological disorders, disturbances of neural transmission, changes in the level of neurotrophic factors, decreased cellular proliferation and neurogenesis, and enhanced the neural death [36]. It needs to be mentioned that AASs effects are dose-dependent, however, they are influenced by personal liability and lifestyle risk factors such as alcohol consumption [8].

Based on previous literature, AAS consumption as lead to memory disorders [37]. As hippocampal neurons play a key role in memory and learning processes, one probable reason for memory impairment is due to the apoptotic effects which cause neural death in the hippocampal area. In addition, stanozolol has demonstrated toxic effects on

NMDA receptors *in vitro* at nanomolar concentrations [19]. Due to the important role of these receptors in memory and learning processes, it is assumed that AAS-induced memory disorders are due to the toxic effect on NMDA receptors.

Our study demonstrated that hippocampal damage is via the induction of apoptosis. It was confirmed by detecting the increase in apoptotic and pre-apoptotic cells in the rats' hippocampi in the stanozolol treated group. These results reveal that the mean number of apoptotic and pre-apoptotic neurons in the experiment group was significantly increased when compared to the control group.

Two factors that are known to play a role in apoptotic cell death are oxidative stress and free radicals. Oxidative stress results in the destruction of cell membranes and intracellular organelles by the activation of chemical

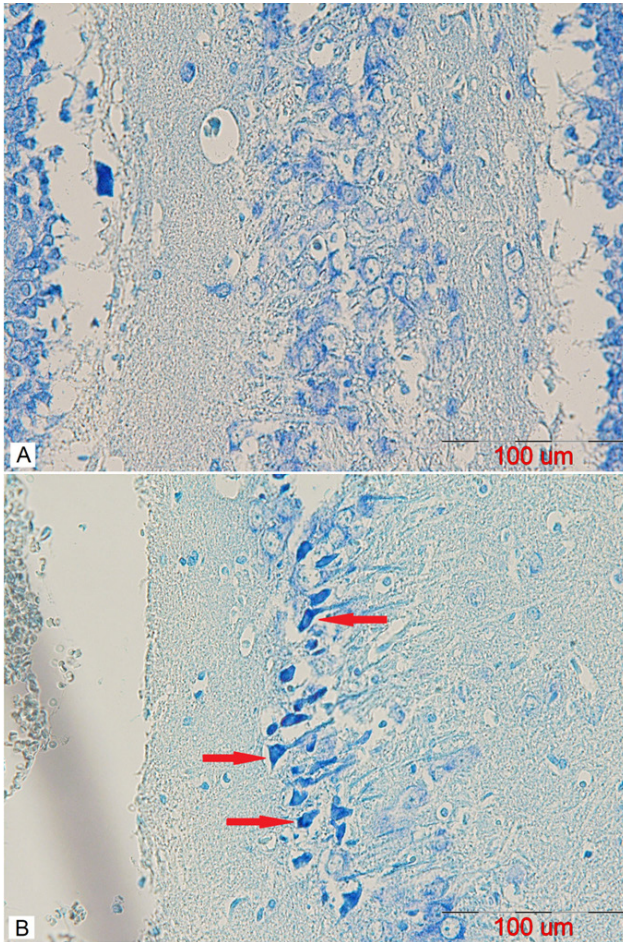


Figure 9: A representative coronal section of the CA3 area of a mature male rat's hippocampus stained using Toluidine Blue to observe pre-apoptotic cells in (A) control and (B) stanozolol treated groups. The arrows indicate dark neurons (scalebar=100μm).

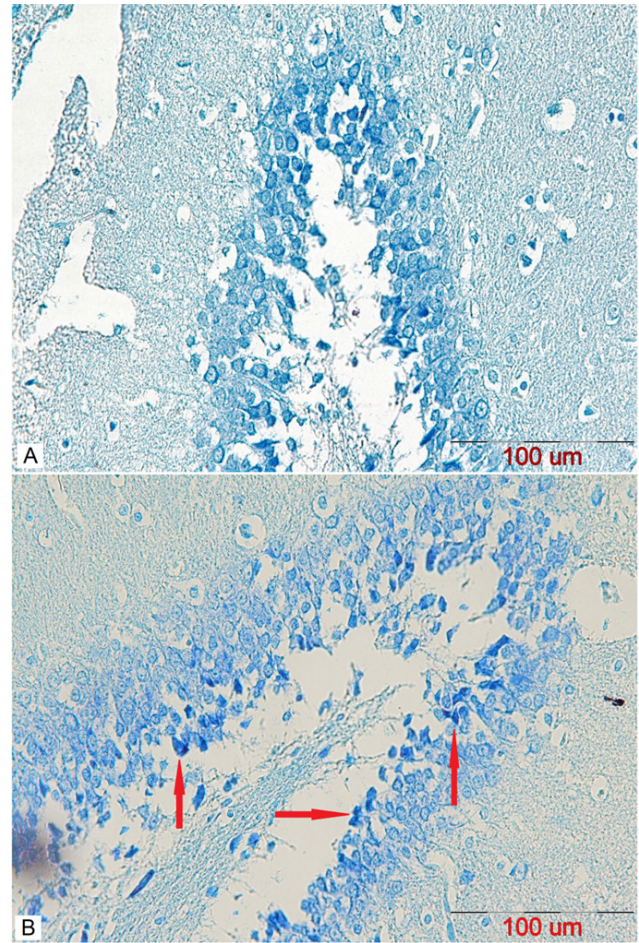


Figure 10: A representative coronal section of the DG area of a mature male rat's hippocampus stained using Toluidine Blue to observe pre-apoptotic cells in (A) control and (B) stanozolol treated groups. The arrows indicate dark neurons (scalebar=100μm).

signalling involved in apoptosis. Considering the confirmed role of stanozolol in causing oxidative stress [38], it can be concluded that one reason for the increase in the number of apoptotic cells in our study is due to oxidative stress.

Conclusion

In conclusion, the anabolic-androgenic steroid stanozolol, as an anabolic-androgenic steroid, caused neural destruction in rat hippocampi by creating apoptotic and pre-apoptotic cells. The hippocampus plays an important role in memory function, therefore, neural damage in this area may induce memory disorders. Future behavioural studies to investigate the formation and severity of memory dysfunction are needed.

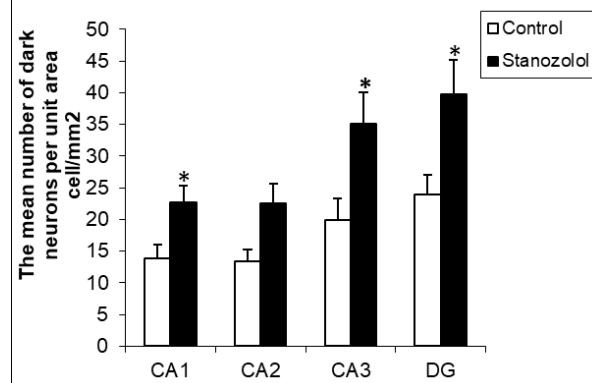


Figure 11: The comparison of the mean number of dark neurons in stanozolol group versus the control group in CA1, CA2, CA3 and DG of areas of mature male rats' hippocampus (mean±SEM). Stanozolol treatment resulted in a statistically significant increase in the number of dark neurons in each brain area when compared to the control group (*p<0.05 in CA1, CA2, CA3, and DG).

Conflict of interest: Authors state no conflict of interest.

References

- Pope HG, Kanayama G. Anabolic–Androgenic Steroids. In: Verster CJ, Brady K, Galanter M, Conrod P, editors. *Drug Abuse and Addiction in Medical Illness: Causes, Consequences and Treatment*. New York, NY: Springer New York; 2012. p. 251-64.
- Maini AA, Maxwell-Scott H, Marks DJ. Severe alkalosis and hypokalemia with stanozolol misuse. *Am J Emerg Med*. 2014;32(2):196 e3-4.
- van Amsterdam J, Opperhuizen A, Hartgens F. Adverse health effects of anabolic-androgenic steroids. *RegulToxicolPharmacol*. 2010;57(1):117-23.
- Matrisciano F, Modafferi AM, Togna GI, Barone Y, Pinna G, Nicoletti F, et al. Repeated anabolic androgenic steroid treatment causes antidepressant-reversible alterations of the hypothalamic-pituitary-adrenal axis, BDNF levels and behavior. *Neuropharmacology*. 2010;58(7):1078-84.
- Beutel A, Bergamaschi CT, Campos RR. Effects of chronic anabolic steroid treatment on tonic and reflex cardiovascular control in male rats. *J Steroid BiochemMol Biol*. 2005;93(1):43-8.
- Musharraf SG, Arfeen QU, Mazhar W, Kanwal N. A validated stability-indicating TLC-densitometric method for the determination of stanozolol in pharmaceutical formulations. *Chem Cent J*. 2013;7(1):142.
- Chesnut CH, 3rd, Ivey JL, Gruber HE, Matthews M, Nelp WB, Sisom K, et al. Stanozolol in postmenopausal osteoporosis: therapeutic efficacy and possible mechanisms of action. *Metabolism*. 1983;32(6):571-80.
- Ampuero J, Garcia ES, Lorenzo MM, Calle R, Ferrero P, Gomez MR. Stanozolol-induced bland cholestasis. *Gastroenterol Hepatol*. 2014;37(2):71-2.
- Clark AS, Harrold EV, Fast AS. Anabolic-androgenic steroid effects on the sexual behavior of intact male rats. *HormBehav*. 1997;31(1):35-46.
- Perry PJ, Yates WR, Andersen KH. Psychiatric Symptoms Associated with Anabolic Steroids: A Controlled, Retrospective Study. *Ann Clin Psychiatry*. 1990;2(1):11-7.
- Maravelias C, Dona A, Stefanidou M, Spiliopoulou C. Adverse effects of anabolic steroids in athletes. A constant threat. *Toxicol Lett*. 2005;158(3):167-75.
- Abu-Shakra S, Alhalabi MS, Nachtman FC, Schemidt RA, Brusilow WS. Anabolic steroids induce injury and apoptosis of differentiated skeletal muscle. *J Neurosci Res*. 1997;47(2):186-97.
- Zaugg M, Jamali NZ, Lucchinetti E, Xu W, Alam M, Shafiq SA, et al. Anabolic-androgenic steroids induce apoptotic cell death in adult rat ventricular myocytes. *J Cell Physiol*. 2001;187(1):90-5.
- Pey A, Saborido A, Blazquez I, Delgado J, Megias A. Effects of prolonged stanozolol treatment on antioxidant enzyme activities, oxidative stress markers, and heat shock protein HSP72 levels in rat liver. *J Steroid BiochemMol Biol*. 2003;87(4-5):269-77.
- Boada LD, Zumbado M, Torres S, Lopez A, Diaz-Chico BN, Cabrera JJ, et al. Evaluation of acute and chronic hepatotoxic effects exerted by anabolic-androgenic steroid stanozolol in adult male rats. *Arch Toxicol*. 1999;73(8-9):465-72.
- Habscheid W, Abele U, Dahm HH. [Severe cholestasis with kidney failure from anabolic steroids in a body builder]. *Dtsch Med Wochenschr*. 1999;124(36):1029-32.
- Sheffer AL, Fearon DT, Austen KF. Clinical and biochemical effects of stanozolol therapy for hereditary angioedema. *J Allergy Clin Immunol*. 1981;68(3):181-7.
- Pomara C, Neri M, Bello S, Fiore C, Riezzo I, Turillazzi E. Neurotoxicity by synthetic androgen steroids: oxidative stress, apoptosis, and neuropathology: A review. *CurrNeuropharmacol*. 2015;13(1):132-45.
- Orlando R, Caruso A, Molinaro G, Motolese M, Matrisciano F, Togna G, et al. Nanomolar concentrations of anabolic-androgenic steroids amplify excitotoxic neuronal death in mixed mouse cortical cultures. *Brain Res*. 2007;1165:21-9.
- Snell RS. *Clinical Neuroanatomy*. Seventh ed. (January 22, 2009). Philadelphia: Wolters Kluwer Health/Lippincott Williams & Wilkins; c2010. 560 p.
- Hall JE. Guyton and Hall: *Textbook of Medical Physiology*. 13th ed. (June 3, 2015). Saunders Imprint. Philadelphia, US. Chapter 59, P759-760.
- Rubinow DR, Schmidt PJ. Androgens, brain, and behavior. *The American Journal of Psychiatry*. 1996;153(8):974-984.
- Bagheri-Abassi F, Alavi H, Mohammadipour A, Motejaded F, Ebrahimzadeh-Bideskan A. The effect of silver nanoparticles on apoptosis and dark neuron production in rat hippocampus. *Iran J Basic Med Sci*. 2015;18(7):644-8.
- Blasberg ME, Clark AS. Anabolic-androgenic steroid effects on sexual receptivity in ovariectomized rats. *Horm Behav*. 1997;32(3):201-8.
- Clark AS, Kelton MC, Whitney AC. Chronic administration of anabolic steroids disrupts pubertal onset and estrous cyclicity in rats. *Biol Reprod*. 2003;68(2):465-71.
- Clark AS, Fast AS. Comparison of the effects of 17 alpha-methyltestosterone, methandrostenolone, and nandrolone decanoate on the sexual behavior of castrated male rats. *Behav Neurosci*. 1996;110(6):1478-86.
- Duchaine D. *Underground Steroid Handbook II: Incorporating Material from the Original Underground Steroid Handbook, Ultimate Muscle Mass, and the USH Updates #1-10*: HLR Technical Books; 1989.
- Pieretti S, Mastriota M, Tucci P, Bataglia G, Trabace L, Nicoletti F, et al. Brain nerve growth factor unbalance induced by anabolic androgenic steroids in rats. *Med Sci Sports Exerc*. 2013;45(1):29-35.
- Kudo K, Wati H, Qiao C, Arita J, Kanba S. Age-related disturbance of memory and CREB phosphorylation in CA1 area of hippocampus of rats. *Brain Res*. 2005;1054(1):30-7.
- Sreekumaran E, Ramakrishna T, Madhav TR, Anandh D, Prabhu BM, Sulekha S, et al. Loss of dendritic connectivity in CA1, CA2, and CA3 neurons in hippocampus in rat under aluminum toxicity: antidotal effect of pyridoxine. *Brain Res Bull*. 2003;59(6):421-7.
- Jekal SJ, Cha HH. Discrimination of early and late apoptotic cells by toluidine blue staining in paraffin-embedded tissues. *The Korean Journal of Clinical Laboratory Science (KJCLS)*. 1998;30:275-90.
- Sadeghi A, Ebrahimzadeh Bideskan A, Alipour F, Fazel A, Haghir H. The Effect of Ascorbic Acid and Garlic Administration

- on Lead-Induced Neural Damage in Rat Offspring's Hippocampus. *Iranian Journal of Basic Medical Sciences*. 2013;16(2):157-64.
33. Abrams JM, White K, Fessler LI, Steller H. Programmed cell death during *Drosophila* embryogenesis. *Development*. 1993;117(1):29-43.
 34. Erenpreisa J, Erenpreiss J, Freivalds T, Slaidina M, Krampe R, Butikova J, et al. Toluidine blue test for sperm DNA integrity and elaboration of image cytometry algorithm. *Cytometry A*. 2003;52(1):19-27.
 35. MohdMusalip SS, Surindar Singh GK, Mohd Shah A, Mohamad M, Mani V, Hussin SN. Histological changes in testes of rats treated with testosterone, nandrolone, and stanozolol. *Iran J Reprod Med*. 2013;11(8):653-8.
 36. Novaes Gomes FG, Fernandes J, Vannucci Campos D, Cassilhas RC, Viana GM, D'Almeida V, et al. The beneficial effects of strength exercise on hippocampal cell proliferation and apoptotic signalling is impaired by anabolic androgenic steroids. *Psychoneuroendocrinology*. 2014;50:106-17.
 37. Bueno A, Carvalho FB, Gutierrez JM, Lhamas C, Andrade CM. A comparative study of the effect of the dose and exposure duration of anabolic androgenic steroids on behavior, cholinergic regulation, and oxidative stress in rats. *PLoS One*. 2017;12(6):e0177623.
 38. Bueno A, Carvalho FB, Gutierrez JM, Lhamas CL, Brusco I, Oliveira SM, et al. Impacts of dose and time of boldenone and stanozolol exposure in inflammatory markers, oxidative and nitrosative stress and histopathological changes in the rat testes. *Theriogenology*. 2017;90:101-8.