

## Research Article

## Open Access

Hamid reza Hemmati, Banafshe Shahnazari, Majid Foroutan\*

# The Effect of Fine needle aspiration on Detecting Malignancy in Thyroid Nodule

<https://doi.org/10.1515/bmc-2019-0012>

received January 20, 2019; accepted March 3, 2019.

**Abstract: Introduction:** The prevalence of thyroid nodules is 4-7% in adults. Although less than 5% of nodules in adults are malignant, most nodules are non-neoplastic or benign. Fine needle aspiration (FNA) is a diagnostic technique for evaluation of non-toxic nodules, which has been widely accepted. Its primary objective is the patient triage in order to identify those who need surgery and aid in the decision of the appropriate surgical procedures.

**Materials and Methods:** This retrospective study was conducted on 116 patients who underwent thyroidectomy in Semnan's Kowsar Hospital during 2011-2018 in Iran. The data were recorded before and after the surgery in the checklist. The data were compared and the sensitivity, specificity and diagnostic accuracy of FNA were calculated. Data were analyzed by SPSS software (version 18.0) and analyzed by Chi-Square test and Independent Samples test.

**Results:** The sensitivity of FNA was 96.9%; its specificity was 81.7%; its positive predictive value (PPV) was 73.8%; its negative predictive value (NPV) was 98%; and its diagnostic accuracy was 86.9%.

For the nodules smaller than 4 cm, FNA was calculated with higher sensitivity, specificity, PPV, NPV, and diagnostic accuracy compared to nodules larger than 4 cm.

**Conclusion:** FNA is a reliable screening method for preoperative assessment that can accurately detect malignant cases from benign cases, especially if the size of the nodule is smaller than 4 cm.

**Keywords:** Thyroid Nodule; Biopsy, Fine-Needle; Thyroidectomy; Cytodiagnosis.

## Introduction

The prevalence of thyroid nodules is 4-7% in adults. Although less than 5% of nodules in adults are malignant [1, 2], most nodules are non-neoplastic or benign. One of the most crucial differential diagnoses is thyroid nodules in thyroid cancer that should not be neglected [3, 4]. Several variables affect the prevalence of thyroid nodules in different populations, including age, gender, and iodine intake. Prevalence increases with age in both genders. The prevalence is higher among women, among the older population, and in areas with iodine deficiency, in a way that 50% of 60-year-old subjects have thyroid nodules [5]. Thyroid nodules in histopathologic studies on the deceased, demonstrated by ultrasound imaging and physical examination, confirmed a high prevalence of benign thyroid nodules among the subjects of a population [6-9]. In children, the prevalence of thyroid nodules is much lower, about 2-6%, although the proportion of malignant nodules to benign nodules is more than that of in adults (9-50% vs. 5-14%) [10-13]. A gold standard diagnostic method for thyroid nodules involves cytology and pathology [14].

Fine needle aspiration (FNA) is widely accepted as a selective diagnostic tool for the evaluation of non-toxic nodules. Its primary objective is to perform the triage, in order to identify the patients that require surgery, and to decide on appropriate surgical procedures. According to the type of lesion, FNA can also have a screening diagnostic role. As a diagnostic method, the purpose of FNA is to detect papillary thyroid cancer and other malignancies [15-18].

Although FNA is one of the most reliable diagnostic methods, there have been many recent attempts to replace it with needle biopsy. The reasons for this choice are to provide more samples, carry out additional studies, and have no need for instruction of cytology interpretation;

\*Corresponding author: **Majid Foroutan**, Internal Medicine Department, School of Medicine, Semnan University of Medical Sciences, Semnan, Iran, E-mail: dr\_foroutan@yahoo.com

**Hamid reza Hemmati:** Department of Surgery, School of Medicine, Semnan University of Medical Sciences, Semnan, Iran

**Banafshe Shahnazari:** School of Medicine, Tehran University of Medical Sciences, Tehran, Iran

of course, only the last reason seems to be applicable [19]. The use of FNA is more cost effective than using any other method [20], has proved its effectiveness as a simple and effective method, and has the same value for all age groups [21].

According to clinical experts, FNA can differentiate benign nodules from malignant nodules and those that require treatment. The routine use of FNA has significantly reduced the number of unnecessary surgeries of thyroid nodules and has led to a two-fold detection of thyroid cancers in pathologic findings [22-24].

The most important indication for FNA is the existence of a solitary nodule, but even in a multinodular goiter with malignancy risk of 7.2%, in which one of the nodules is bold or its consistency is changed, as well as in some cases of Graves' disease and Hashimoto's thyroiditis, which have abnormal localized area, it is recommended to perform FNA and it has been globally accepted [25-27].

The diagnosis of follicular carcinoma and Hurthle cell carcinoma requires observation of invasion to the thyroid vessels or thyroid capsule, from which thyroid cancer begins. It is not specified in FNA; therefore, the need for thyroidectomy or lobectomy is defined for them [28, 29].

Given the high prevalence of thyroid nodules, research in this regard is in line with the research priorities of the Ministry of Health [30]; however, there has not been any study on the accuracy of thyroid nodules in Semnan province. Besides, considering the importance of the subject and the fact that the rate of sensitivity in this test differs from one study to another, and since rapid diagnosis with high confidence level can prevent unnecessary surgeries and high costs for patients and the hospital, Considering the increase among the average age population and the prevalence of thyroid nodules and, on the other hand, the long treatment period, the results of this plan will have a significant role in reducing health costs. Therefore, the researchers decided to make a comparison between cytologic and pathologic findings in samples from aspiration of thyroid nodules in Semnan.

## Materials and Methods

**Objective:** To determine the diagnostic value of cytology of FNA in detecting malignancy of thyroid nodules.

**Design:** This retrospective study with a registration number in a clinical trial was conducted on all patients who underwent thyroidectomy (lobectomy or total thyroidectomy) in the surgery ward and endocrine clinic of Kowsar Hospital, in Semnan city, from 2011 to 2018.

**Participants:** Inclusion criteria included the ages 15 and older, those who gave their consent to participate in the project, and those who had postoperative pathology report. Exclusion criteria included a number of patients who underwent a thyroidectomy and had postoperative pathological report, but there was no FNA histological result available.

**Intervention:** Firstly, patients who underwent thyroidectomy (lobectomy or total thyroidectomy) in Kowsar Hospital affiliated to Semnan University of Medical Sciences from 2011 to 2018 were identified; then 116 patients who had pathological reports were recruited in the study using convenience-sampling method, considering inclusion and exclusion criteria, and after taking their written consent forms. The data collection tool was based on a checklist of patients' information that included personal characteristics, FNA results, and postoperative pathological report. Data were compared to other similar studies and were recorded, and finally their reliability and validity were confirmed.

Since there are other criteria other than FNA for performing the thyroidectomy, regardless of the outcome of FNA, in all patients' postoperative pathological findings were compared with preoperative cytological findings that could be benign or malignant.

In this study, the preoperative characteristics, including the nodule size, the nodule type, and the number of performing FNA, as well as the postoperative characteristics, including performed surgery and the results of pathology were recorded in the checklist. Then, the data were compared and the sensitivity, specificity and accuracy of FNA were calculated.

Therefore, the diagnostic accuracy of the test for diagnosis of malignancy was investigated among patients who had undergone thyroidectomy.

**Ethical considerations:** Initially, the objective of the study and the procedure was explained to the participants. They were assured that their information, such as their phone number, would remain confidential and be used for scientific purpose only. The surveys would not impose any costs on the subjects. After obtaining the informed consent forms from the subjects, they were recruited into the study.

**Statistical methods:** Data were entered into SPSS software (version 18.0). Then extraction of patients' characteristics, sensitivity, specificity, and PPV and NPV of cytology were determined. Chi-Square Test and Independent Samples Test were the statistical analyses used in this study.

**Ethical approval:** The research related to human use has been complied with all the relevant national regulations, institutional policies and in accordance the tenets of the Helsinki Declaration, and has been approved by Semnan University of Medical Ethics Committee (IR. SEMUMS. REC.1396.131).

**Informed consent:** Informed consent has been obtained from all individuals included in this study.

## Results

According to the results of the study, the mean age of the patients was  $45.16 \pm 13.65$  years. The majority of subjects (83.3%) were female. The main complaints of patients were neck mass, hand tremor, palpitations, and sweating.

In terms of thyroid nodule size, 38.8% of subjects had a size of 0-3.9 cm, and 61.2% had a size larger than 4 cm. Concerning the type of nodules, 39.7% of patients had solid-cystic nodule, 54.3% had solid nodule, and 6% had cystic nodule.

The results of FNA illustrated that 18.1% of subjects were suspected to have malignancy; 19% had follicular neoplasm; 17.2% had thyroid papillary carcinoma; 0.9% had atypia of undetermined significance (AUS), and there was one non-diagnostic case; 43.1% were benign; in 0.9%, malignant Hurthle cell was diagnosed (Figure 1).

According to the type of performed surgery, 50% of subjects underwent total thyroidectomy; 25.9% had right lobectomy ismechtomy, 10.3% had left lobectomy ismechtomy, and 13.8% underwent near total thyroidectomy.

Follicular adenoma was found in 15 cases (12.9%); thyroid follicular carcinoma was seen in 12 cases (10.3%); thyroid papillary carcinoma was found in 29 cases (25%); while multinodular goiter was seen in 37 cases (31.9%); nodular goiter was found in 13 cases (11.2%), simple goiter was seen in 3 cases (2.6%); and Hashimoto’s thyroiditis was seen in 7 cases (6%) (Figure 2).

The coefficient of agreement or Kappa was calculated in the study of 0.732. There was no significant relationship between the size of thyroid nodule and malignancy ( $p = 0.292$ ). There was no significant association between gender and malignancy ( $p = 0.596$ ). According to the results of the study, most of the malignant nodules were of solid type and most of the cystic-solid and cystic nodules were benign. In general, diagnostic monitors evaluated all nodules of higher and lower than 4 cm (Table 2).

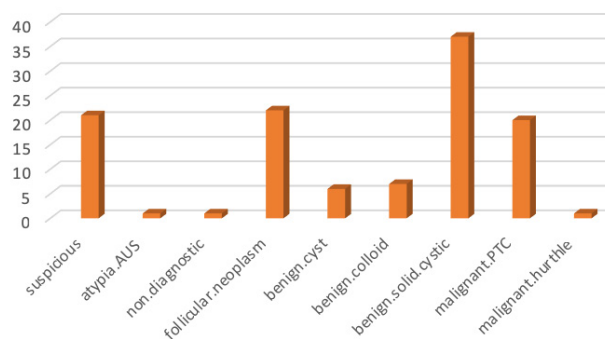


Figure 1: Frequency comparison of FNA results.

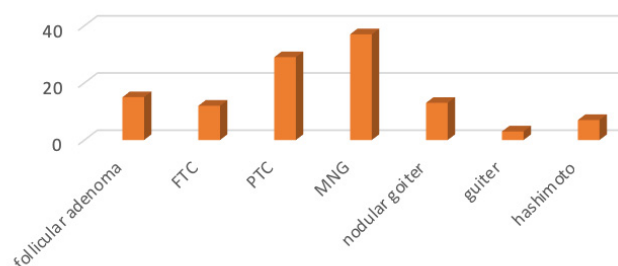


Figure 2: Frequency comparison of pathologic results of thyroid nodules.

Table 1: Coordination of pathological and FNA results in patients undergoing thyroidectomy

Pathology result	FNA				Total	
	Malignant		Benign		count	%
	count	%	count	%		
Malignant	31	96.9	1	3.1	32	34.8
Benign	11	18.3	49	81.7	60	65.2
Total	42	100	50	100	92	100

In this study, the subjects whose FNA results were follicular neoplasm were not included in the preliminary study to determine sensitivity and specificity, because the test was not able to differentiate between follicular malignancy and benign follicular adenoma, but their results were separately compared with postoperative pathological findings.

Out of 116 subjects, in the FNA, results of 22 patients there were follicular neoplasm, of which 10 patients had follicular carcinoma, 10 patients had follicular adenomas, one subject had nodular goiter, and one had Hashimoto’s thyroiditis.

**Table 2:** Evaluation of diagnostic tests in nodules lower than 4 cm

Nodules higher than 4 cm				Nodules lower than 4 cm			
Negative predictive value	Positive predictive value	Property	Sensitivity	Negative predictive value	Positive predictive value	Property	Sensitivity
96%	70%	79%	95%	100%	80%	85%	100%

## Discussion

In the present study, FNA had a sensitivity of 96.9%, specificity of 81.7%, PPV of 73.8%, NPV of 98%, and accuracy of 86.9%. Considering its high diagnostic accuracy, it was an appropriate screening test to evaluate thyroid nodules. However, for solid nodules due to low specificity and PPV (40% and 78% for nodules below 4 cm and 25% and 72% for nodules above 4 cm, respectively), FNA did not play a significant role.

In a study by Solati et al., 31 women and 13 men were studied. Out of 44 cases of FNA, 6 cases (13.6%) were non-diagnostic; in 14 cases (31.8%), the response was vague; in 15 cases (34.1%), benign tumors, and in 9 cases (20.5%), malignant tumors were reported. Compared to those that received biopsy, FNA results showed a sensitivity of 87.5%, specificity of 100%, accuracy of 97.4%, PPV of 100%, and NPV of 96.8% for the detection of malignancy in the thyroid nodule. The results emphasized the importance of FNA as a simple, low-cost, non-invasive method, and if it was carefully performed and evaluated by an experienced pathologist, it would have high sensitivity and specificity [31].

In the present study, the results demonstrated that FNA had a sensitivity of 96.9%, specificity of 81.7%, PPV of 73.7%, NPV of 98%, and diagnostic accuracy of 86.9%, which differed from the results of the Sabeti et al. study; for instance, our study demonstrated that the specificity and PPV were lower, while the sensitivity and NPV were higher. Besides, the diagnostic accuracy in our test was lower than in the previously mentioned research. The reason for these differences could be due to the fact that FNA cases that were non-diagnostic or had vague results that were more present in the Solati et al. study [31].

In the study of Yang et al., out of 4703 patients, 1052 patients were followed up by surgery, including 14.9% of patients whose FNA response was inadequate; 9.8% of patients had benign results in FNA; 40.6% of patients showed atypical cells in FNA; 63.1% of patients whose responses to FNA were follicular neoplasm; 86.1% of patients whose FNA results were suspected to be malignant; and 79.3% of patients whose FNA results were malignant. The rates of histologically confirmed

malignancy in these patients were 10.9%, 7.3%, 13.5%, 32.2%, 64.7% and 98.6%, respectively.

The diagnostic difference between cytological findings of FNA and postoperative pathological results was 15.3%. This difference was due to inadequate samples, badly prepared samples, and overlapping of cytological characteristics in hyperplastic nodules and follicular adenomas. The sensitivity and specificity of FNA for diagnosis of malignancy in this study were 94% and 98.5%, respectively. These results showed that FNA was a precise diagnostic method for malignancy in thyroid nodules [32].

By comparing the results of our study with the study conducted by Yang et al., and considering the large difference between the number of samples in both studies, we found that FNA in both studies had high sensitivity (96.9% in our study vs. 94% in their study), while the specificity in our study was lower (81.7% vs. 98.5%). This difference could be due to the difference in the pathologist's interpretation of FNA's cytological results in both studies, or because of considering the samples with follicular neoplasm in the above-mentioned study [32].

In a study by Sanjari et al., 218 cases of FNA were studied and their cytological results suggested benignity in 57.8% of cases, and malignancy in 19.7% of cases; while 20.2% of cases were suspected and 1.4% were non-diagnostic. FNA sensitivity was 72.5%, its specificity was 83%, and the accuracy was 76%. In addition, the false negative rate in their test was 19% and false positive rate was 24%.

The sensitivity, specificity and accuracy of thyroid FNA in the present study were lower than those of other countries. A remarkable point in this study was the low incidence (1.4%) of non-diagnostic cases compared to other studies (17%), and high incidence of false negative rates (19%) compared to other studies (5.2%). In sum, it seemed that FNA biopsy was a meticulous and cost-effective way to determine the type of thyroid nodule.

Compared to the present study, the study of Sanjari et al. had a lower sensitivity (72.5% vs. 96.9%), almost the same specificity (83% vs. 81.7%) and a lower accuracy (76% vs. 86%), which could be due to the existence of false negative rates in their research [33].



In both mentioned studies, it can be concluded that FNA is still the first and the best diagnostic tool for evaluating thyroid nodules and determining the treatment of patients with this complaint. If an expert physician performs FNA and the results are well interpreted by a qualified pathologist, the sensitivity and specificity and other statistical characteristics will be added and will be more accurately diagnosed.

In the study of Riyazi et al., for 158 (79.8%) patients who underwent thyroid FNA, benign lesions were detected; while for 17 patients (8.6%) malignancy and for 23 patients (11.6%) suspected or unclear results were reported. Sensitivity (53.84%), specificity (98.1%), PPV (82.35%), NPV (92.5%), and diagnostic accuracy (81.81%) were obtained for thyroid FNA.

In this study, the diagnostic method of thyroid FNA, as a preoperative diagnostic method, did not have enough sensitivity to detect malignant lesions and should have considered the clinical findings, sonography, and biological markers in preoperative management of thyroid nodules surgery.

Comparing the results of our study with the study of Riazi et al., it was discovered that sensitivity was higher in our research, (96.9% vs. 53.84%), while the specificity of our study was lower (81.7% vs. 98.1%). Moreover, PPV was lower (73.8% vs. 82.35%), NPV was higher (98% vs. 92.5%), and diagnostic accuracy was higher (86.9% vs. 81.81%). Regarding the low sensitivity of the study of Riazi et al., it was suggested to compare the results of FNA with other findings, including clinical, sonographic, and biomarker findings, in order to increase the sensitivity and diagnostic accuracy of the test [34].

In the study of Ezzat et al., which was conducted on 296 patients, 98 patients (33.1%) had benign lesions; 40 cases (13.5%) were classified as follicular lesions of undetermined diagnostic value; 49 subjects (16.5%) had follicular neoplasm; 30 patients (10.1%) were suspected to be malignant; 58 cases (19.5%) were malignant; and 21 cases (7.1%) had insufficient samples. Nodular hyperplasia included a large proportion of benign cases (89.8%), while the papillary thyroid carcinoma was the most malignant lesions (72.4%).

The cytological results of FNA were compared with histopathologic results after thyroid surgery. In the present study, FNA had a sensitivity of approximately 92.8%, specificity of 94.2%, PPV of 94.9%, NPV of 91.8%, and diagnostic accuracy of 91%. In this study, it was concluded that FNA was a sensitive test with a high specificity and good accuracy to evaluate patients with thyroid nodule complaints [35].

Compared to the present study, the study conducted by Ezzat et al. had a lower sensitivity. In our study, the specificity and PPV were lower than in theirs, but NPV in our study was lower. Moreover, the diagnostic accuracy in our research was lower. From the overall comparison of both studies, it was found that FNA was an appropriate screening diagnostic test with high sensitivity and specificity for the assessment of thyroid nodules.

In the study of Sclubas et al., which was performed on 240 patients, the results of the FNA were 76 (32%) positive cases for malignancy, 53 (22%) cases were malignant, in 100 (42%) of the cases the malignancy was unclear and 11 cases (5%) were non-cognitive. Also, 3 cases (4%) were false positive and 2 (4%) cases were false negative. Among 100 uncertain cases of FNA, in 11 cases (15%), 73 cases of follicular neoplasm, 2 cases (20%) of 10 cases of Herpes simplex neoplasms and 14 (82%) of 17 suspected cases of papillary carcinoma, thyroid malignancy was diagnosed. In 73 patients with follicular neoplasm, the diameter of the nodule above 2 cm was associated with a high risk of malignancy. However, our study demonstrated that there was no significant relationship between the size of the nodule with malignant risk. The false negative results of FNA were uncommon among patients with unspecified results and the subgroup of patients with the results of thin aspirated cases suspected of papillary carcinoma and follicular neoplasms had the highest risk for malignancy [36]. Due to the high sensitivity and the appropriateness of the method, and with positive predictive value and negative predictive value, it could be suggested that FNA is still considered as a reliable screening method for the evaluation of pre-operative thyroid nodules.

## Conclusion

It can be concluded that FNA is a sensitive test with high specificity; and considering its high diagnostic accuracy, it is an appropriate and efficient screening test in the evaluation of thyroid nodules. FNA, as a preoperative screening method, was reliable to evaluate nodules of smaller than 4 cm and could accurately detect malignant cases from benign cases. However, given its low PPV and diagnostic accuracy to detect malignancy of nodules of bigger than 4 cm (70% and 68%, respectively), it is recommended to perform further evaluation for these nodules and the patients with negative FNA results should undergo surgery.

## Suggestions for the future

This study, like any other study, has a number of limitations. Considering the wide range of issues, this study requires further studies that will investigate the following limitations listed below: Other researches are recommended: 1. By increasing the sample size, the test power can be increased. 2. Several centers are to be used for study, which imposes a centralized study of the selection error on the study. 3. It is also suggested that a prospective study be conducted to determine the needle aspiration parameters.

**Acknowledgements:** Current paper has been extracted from a medical student dissertation in Semnan University of Medical Sciences. The dissertation was approved as a research project with a registration number in a clinical trial. The researchers would like to express their deepest gratitude to the Research and Technology Deputy of the mentioned university, and also to the staff and patients of the surgery ward and the endocrine clinic of Semnan's Kowsar Hospital.

**Funding:** The reported research in this publication was supported by a grant [number: A-10-66-6] from Semnan University of Medical Sciences, Semnan, Iran.

**Conflict of interest:** Authors state no conflict of interest

## References

- Schlumberger M, Pacini F, Wiersinga WM, Toft A, Smit JW, Franco FS, et al. Follow-up and management of differentiated thyroid carcinoma: a European perspective in clinical practice. *European Journal of Endocrinology* 2004;151(5):539-548.
- Hegedüs L. The thyroid nodule. *New England Journal of Medicine* 2004;351(17):1764-1771.
- Roman SA. Endocrine tumors: evaluation of the thyroid nodule. *Current opinion in oncology* 2003;15(1):66-70.
- Salabe G. Pathogenesis of thyroid nodules: histological classification? *Biomedicine & pharmacotherapy* 2001;55(1):39-53.
- Samiee Rad F, Jahani Hashemi H, Fallah Abed M, Sofiabadi M. A Comparative Study of Sonography and Fine Needle Aspiration Cytology Results in Diagnosis of Thyroid Nodules among the Patients Referred to Qazvin Medical Centers. 2018.
- Fusco A, Chiappetta G, Hui P, Garcia-Rostan G, Golden L, Kinder BK, et al. Assessment of RET/PTC oncogene activation and clonality in thyroid nodules with incomplete morphological evidence of papillary carcinoma: a search for the early precursors of papillary cancer. *The American journal of pathology* 2002;160(6):2157-2167.
- Brunicaudi F, Andersen D, Billiar T, Dunn D, Hunter J, Matthews J, et al. *Schwartz's principles of surgery*, 10e: McGraw-hill; 2014.
- Martinez J, Palermo C, González F, Laboy I. Overview of thyroid physiology: an essential for understanding familial euthyroid multinodular goiter. *Boletín de la Asociación Médica de Puerto Rico* 2013;105(2):68-71.
- Takahashi T, Fujimori K, Simon SL, Bechtner G, Edwards R, Trott KR. Thyroid nodules, thyroid function and dietary iodine in the Marshall Islands. *International journal of epidemiology* 1999;28(4):742-749.
- Krohn K, Paschke R. Somatic mutations in thyroid nodular disease. *Molecular genetics and metabolism* 2002;75(3):202-208.
- Spiezia S, Farina R, Cerbone G, Assanti AP, Iovino V, Siciliani M, et al. Analysis of color Doppler signal intensity variation after levovist injection: a new approach to the diagnosis of thyroid nodules. *Journal of ultrasound in medicine* 2001;20(3):223-231.
- Soori H, Rafiei E, Entezami N, Hasani J, Hossaini SM. A comparison study on rate and causes of under 5 years old deaths in Iran, eastern Mediterranean region and the world. *Safety Promotion and Injury Prevention* 2016;4(1):1-8.
- Moradzadeh M. Frequency of minor salivary glands tumors in patients referred to pathology department of Imam Reza hospital in the last decade (80-89). 2018.
- Hershman JM, Cheng S-y, Gianoukakis AG. Update in thyroidology 2010. *The Journal of Clinical Endocrinology & Metabolism* 2011;96(1):9-14.
- Norlén O, Charlton A, Sarkis LM, Henwood T, Shun A, Gill AJ, et al. Risk of malignancy for each Bethesda class in pediatric thyroid nodules. *Journal of pediatric surgery* 2015;50(7):1147-1149.
- Bouvet M, Feldman JI, Nahum AM, Robbins KT, Gill GN, Dillmann WH, et al. Surgical management of the thyroid nodule: patient selection based on the results of fine-needle aspiration cytology. *The Laryngoscope* 1992;102(12):1353-1356.
- Sutton D. The Pancreas, Chapter 26, *Textbook of radiology and imaging* 7th edn. In.: Elsevier Churchill Livingstone; 2003.
- Castro MR, Gharib H. Continuing controversies in the management of thyroid nodules. *Annals of internal medicine* 2005;142(11):926-931.
- Schmitt F. Thyroid cytology: FNA is still the best diagnostic approach. *Cytopathology* 2006;17(4):211-212.
- Shojaei S, Yousefi M, Ebrahimipour H, Valinejadi A, Tabesh H, Fazaeli S. Catastrophic health expenditures and impoverishment in the households receiving expensive interventions before and after health sector evolution plan in Iran: Evidence from a big hospital. *Koomesh* 2018:283-290.
- Arda I, Yildirim S, Demirhan B, Firat S. Fine needle aspiration biopsy of thyroid nodules. *Archives of disease in childhood* 2001;85(4):313-317.
- Nam-Goong IS, Kim HY, Gong G, Lee HK, Hong SJ, Kim WB, et al. Ultrasonography-guided fine-needle aspiration of thyroid incidentaloma: correlation with pathological findings. *Clinical endocrinology* 2004;60(1):21-28.
- Sohn Y-M, Kwak JY, Kim E-K, Moon HJ, Kim SJ, Kim MJ. Diagnostic approach for evaluation of lymph node metastasis from thyroid cancer using ultrasound and fine-needle aspiration biopsy. *American Journal of Roentgenology* 2010;194(1):38-43.
- Bahar A, ZKashi Z, Akha O. The result of fine-needle-aspiration of thyroid nodule in patient referred to Imam Hospital Sari 2003-

2011. Journal of Mazandaran University of Medical Sciences 2012;22(90):11-16.
25. Werga P, Wallin G, Skoog L, Hamberger B: Expanding role of fine-needle aspiration cytology in thyroid diagnosis and management. *World journal of surgery* 2000;24(8):907-912.
  26. Cooper DS, Doherty GM, Haugen BR, Kloos RT, Lee SL, Mandel SJ, et al. Revised American Thyroid Association management guidelines for patients with thyroid nodules and differentiated thyroid cancer: the American Thyroid Association (ATA) guidelines taskforce on thyroid nodules and differentiated thyroid cancer. *Thyroid* 2009;19(11):1167-1214.
  27. Caruso D, Mazzaferri EL. Fine needle aspiration biopsy in the management of thyroid nodules. *The Endocrinologist* 1991;1(3):194-202.
  28. Joseph UA, Jhingran SG. Graves' disease and concurrent thyroid carcinoma. The importance of thyroid scintigraphy in Graves' disease. *Clinical nuclear medicine* 1995;20(5):416-418.
  29. Howlader N, Noone A, Krapcho M, Neyman N, Aminou R, Altekruse S, et al. SEER cancer statistics review, 1975-2009 (vintage 2009 populations), National Cancer Institute. Bethesda, MD. In.; 2012.
  30. Valinejadi A, Sadoughi F, Salehi M. Diabetes knowledge translation status in developing countries: A mixed method study among diabetes researchers in case of Iran. *International journal of preventive medicine* 2016, 7.
  31. Solati S, Mirzania H, Sobhani S, Eshraghian A, Mehrnush V. Evaluation of results of fine needle aspiration and pathology of thyroid nodules in thyroidectomy patients. *Hormozgan Medical Journal* 2011;14(4):262-270.
  32. Yang J, Schnadig V, Logrono R, Wasserman PG. Fine-needle aspiration of thyroid nodules: a study of 4703 patients with histologic and clinical correlations. *Cancer Cytopathology* 2007;111(5):306-315.
  33. Vander JB, Gaston EA, Dawber TR. The significance of nontoxic thyroid nodules: final report of a 15-year study of the incidence of thyroid malignancy. *Annals of internal medicine* 1968;69(3):537-540.
  34. Riaz A, Eghbali SS, Bahmanyar M, Farzaneh M, Motlagh FR, Motamed N, et al. Correlation of fine needle aspiration of the thyroid with final histopathology in 198 thyroidectomized patients. *Ṭıbb-i junüb* 2013;16(1):37-48.
  35. Sinna E, Ezzat N. Diagnostic accuracy of fine needle aspiration cytology in thyroid lesions. *Journal of the Egyptian National Cancer Institute* 2012;24(2):63-70.
  36. Sclabas GM, Staerkel GA, Shapiro SE, Fornage BD, Sherman SI, Vassilopoulou-Sellin R, et al. Fine-needle aspiration of the thyroid and correlation with histopathology in a contemporary series of 240 patients. *The American Journal of Surgery* 2003;186(6):702-710.